Pritti *et al.*
Egyptian Journal of Medical Human Genetics (2023) 24:42
https://doi.org/10.1186/s43042-023-00420-2

Egyptian Journal of Medical Human Genetics

CASE REPORT

Open Access

Genetic tool used to diagnose achromatopsia: first case report from India

Kumari Pritti[1*], Vineet Mishra[1], Udhaya Kotecha[2] and Somesh Aggarwal[3]

Abstract

Background Achromatopsia is an autosomal recessive disease characterized by poor visual acuity, lack of color vision, nystagmus, and marked photophobia. The symptoms can be extremely disabling, and at present, there is no cure available. Mutations in the *CNGA3, CNGB3, GNAT2, PDE6C, PDE6H,* and *ATF6* genes have been identified as associated with this disease. The genetic approach for these patients is currently an important issue, and gene therapy is an ongoing therapeutic option already being studied in clinical trials.

Case presentation We report the case of two siblings (8 and 5 years old) affected by achromatopsia. They carry compound heterozygous mutations in the *CNGA3* gene at positions 1306 and 1279 in exon 8 (c.1306C > T, p.Arg436Trp and c.1279C > T, p.Arg427Cys). The parents were found to have one of the variants in a heterozygous condition. This is the first reported case of achromatopsia in India.

Conclusion This report emphasizes the importance of genetic testing in such patients, which can aid not only in the diagnosis and management but also in providing counseling to parents regarding the significance of prenatal diagnosis in future pregnancies, helping them make informed choices. Due to its variable presentation, the diagnosis of achromatopsia may be challenging, and exome sequencing has proven to be a crucial diagnostic tool.

Keywords Exome sequencing, Achromatopsia, Genetic testing, Compound heterozygous, Prenatal diagnosis

Background

Achromatopsia is a rare congenital ocular disorder primarily involving cones and inherited in an autosomal recessive manner, with an estimated prevalence of 1:30,000 individuals [1]. Patients typically present in infancy with photophobia, followed by low visual acuity, nystagmus, and an inability to discriminate colors. Electroretinography (ERG) reveals little to no cone function with normal rod function. Fundoscopy is usually normal, although macular pigmentary changes and atrophy have been described [2, 3]. Achromatopsia is caused by mutations in six genes: *ATF6, CNGA3, CNGB3, GNAT2, PDE6C,* or *PDE6* [4–6]. These genes encode proteins that are specifically expressed in cone photoreceptors and are crucial for cone phototransduction.

Most individuals present with complete achromatopsia where there is a total lack of function of all three types of cone photoreceptors. Rarely, individuals have incomplete achromatopsia, in which one or more cone types may be partially functional along with the rods, resulting in milder symptoms [1]. The majority of individuals with biallelic pathogenic variants in *ATF6, CNGA3, CNGB3, GNAT2,* and *PDE6C* exhibit complete achromatopsia with similar clinical features.

Here, we report the cases of two siblings (8 and 5 years old) who were diagnosed with achromatopsia after genetic analysis.

*Correspondence:
Kumari Pritti
preeti.ikdrc@gmail.com
[1] Department of Obstetrics and Gynecology, Institute of Kidney Diseases and Research Centre, Dr HL Trivedi Institute of Transplantation Sciences (IKDRC-ITS), Civil Hospital Campus, Asarwa, Ahmedabad 380016, India
[2] Division of Inherited Disorders, Neuberg Center for Genomic Medicine, Ahmedabad, India
[3] M & J Regional Institute of Ophthalmology, Ahmedabad, India

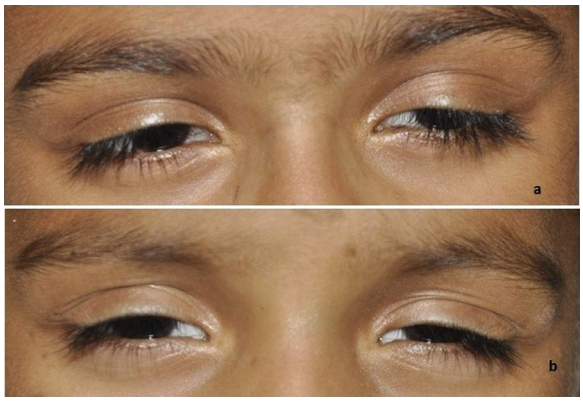

Fig. 1 On exposure to sunlight, **a** the elder and **b** the younger sibling could not keep their eyes open (photophobia)

Case presentation

Two sisters, aged 8 and 5 years, were referred to our department for genetic consultation. They were born to non-consanguineous parents with no significant family history. The main reason for referral was their photophobia (Fig. 1). They recently underwent vision testing and were prescribed spectacles. Fundoscopy revealed normal findings.

Given the presence of a similar disorder in both siblings, a genetic disorder was suspected, and exome sequencing was recommended for the elder sibling. The exome sequencing identified compound heterozygous mutations in the *CNGA3* gene at positions 1306 and 1279 in exon 8 (c.1306C > T, p.Arg436Trp, and c.1279C > T, p.Arg427Cys). Sanger sequencing was performed on the other sibling and the parents to evaluate the same variants (Figs. 2, 3). The parents were found to have one of the variants in a heterozygous condition, while the affected sibling had the same compound heterozygous variants as her elder sister (Figs. 2, 3).

Given the specific genetic defect identified, the affected sisters underwent a detailed clinical examination to assess the extent of the condition. Fundoscopy and electroretinogram (ERG) data were obtained for both sisters (Fig. 4). Visual acuity and color differentiation tests using standard Ishihara plates were performed. The elder sister exhibited the best-corrected

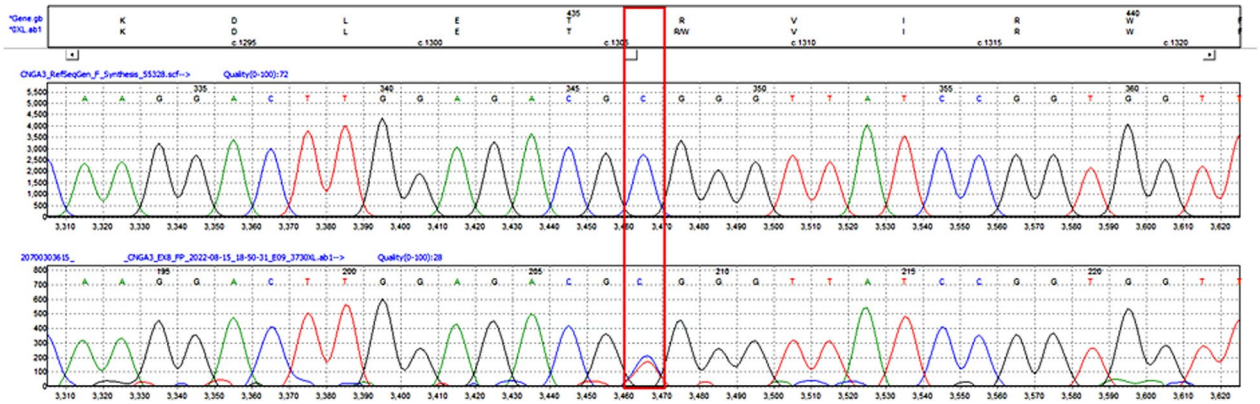

Fig. 2 Sanger sequencing chromatogram of younger sister showing heterozygous status for c.1306C > T(p.Arg436Trp) variant in the *CNGA3* gene

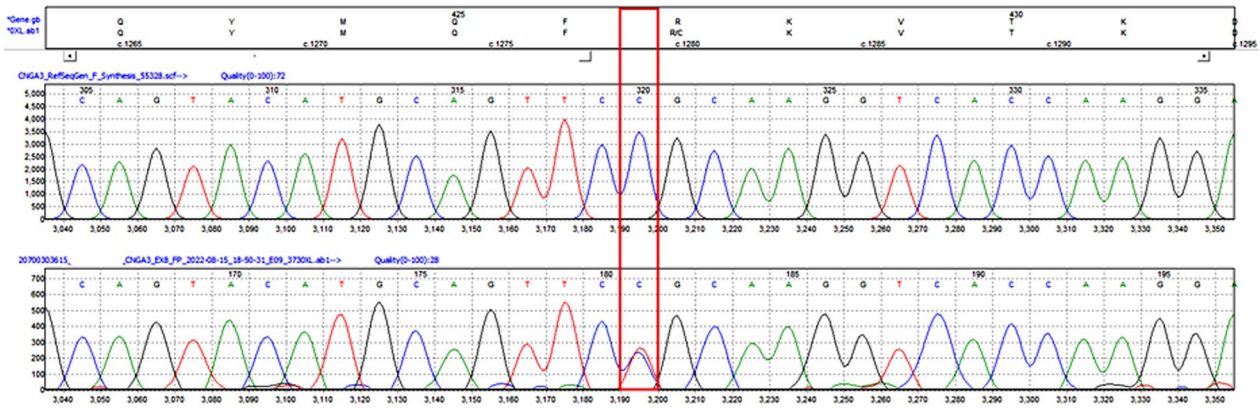

Fig. 3 Sanger sequencing chromatogram of younger sister showing heterozygous status for c.1279C > T(p.Arg427Cys) variant in the *CNGA3* gene

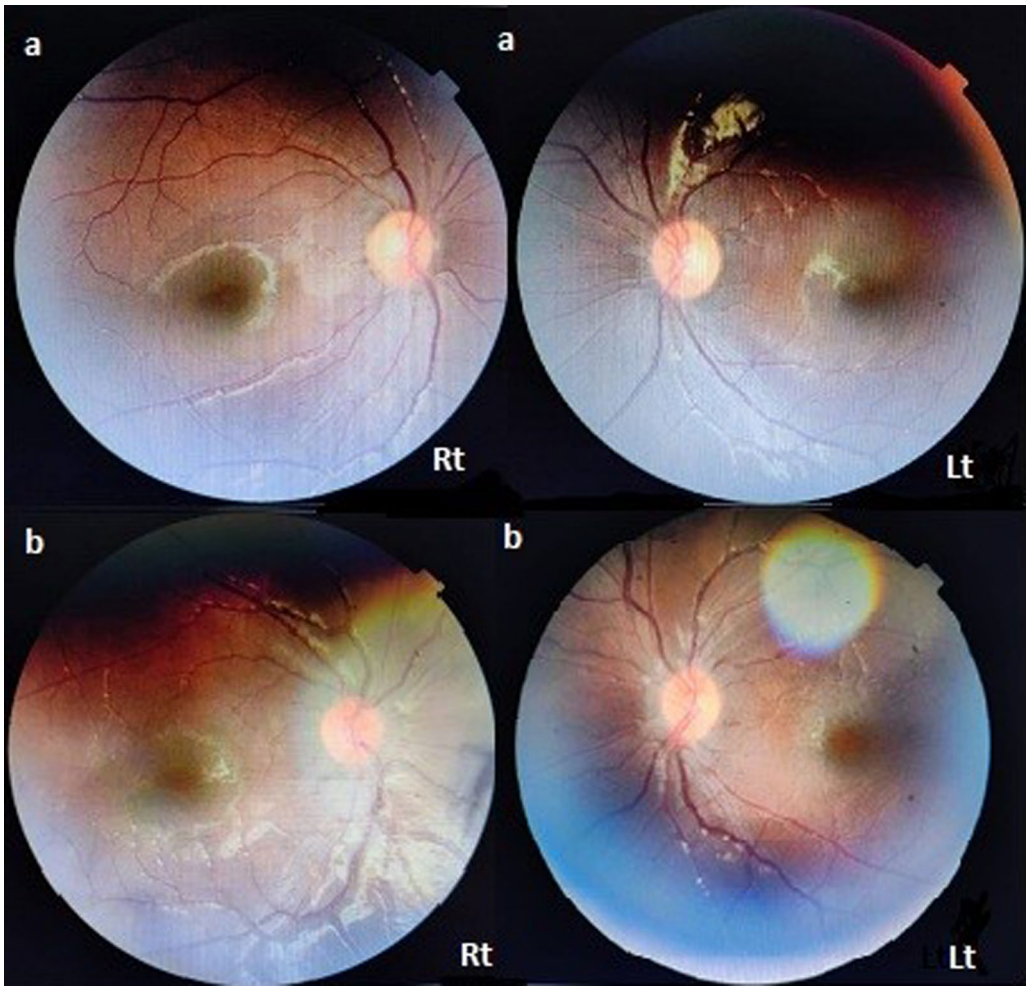

Fig. 4 Fundus photograph of the right and left eyes shows a relatively unremarkable posterior segment. There is a mild hypopigmentation in the macula of both eyes of both the sisters. **a** Elder sister—Right & Left eye, **b** Younger sister—Right and Left eye

visual acuity in both eyes at four meters, with defective color vision. The younger sister was less cooperative, and the tests could not be accurately conducted. However, she also showed reduced vision and defective color vision. Both sisters were advised to use pink glasses to alleviate photophobia. Follow-up appointments every six months were recommended to monitor the progression of the disease.

Discussion

In this case report, we identified two siblings with achromatopsia. Although they presented with symptoms in their first year of life, it took seven years to reach a diagnosis. Achromatopsia is a rare macular dystrophy with variable presentation, which contributes to the diagnostic challenges. Both sisters experienced long-standing visual dysfunction accompanied by photophobia. Genetic analysis of the two sisters with retinal disease led to the correct diagnosis of achromatopsia.

Differential diagnoses for early-onset maculopathies associated with visual impairment are varied, including Best's disease, hypoplastic fovea associated with ocular albinism, inverse retinitis pigmentosa, cone/cone–rod dystrophies, and Stargardt's disease [7, 8]. Genetic testing is crucial to confirm the diagnosis in such cases. Molecular genetic testing approaches that can be considered include targeted analysis for common variants, the use of a multigene panel, or comprehensive genomic testing, typically exome sequencing [9]. In our case, known mutations were identified in *CNGA3* (c.1306C > T, p.Arg436Trp, and c.1279C > T, p.Arg427Cys). CNGA3 channels play a critical role in

cone-mediated vision, which is essential for central and color vision, as well as visual acuity.

To assess the extent of the disease and the requirements of a child diagnosed with achromatopsia, a standard clinical ophthalmologic evaluation is necessary, including assessment of visual acuity and the use of spectacles and/or contact lenses, as well as color vision evaluation. Consultation with a clinical geneticist and/or genetic counselor should also be recommended. Although achromatopsia cannot be cured, it can be effectively managed through early intervention, such as advising the use of dark or special filter glasses or red-tinted contact lenses, which can reduce photophobia and potentially improve visual acuity [10].

Heterozygotes (carriers) are asymptomatic and not at the risk of developing the disorder. However, if both parents are carriers, each pregnancy carries a 25% risk of the child being affected, a 50% risk of being an asymptomatic carrier, and a 25% chance of being unaffected and not a carrier. Therefore, molecular diagnosis is important to counsel parents regarding prenatal diagnosis or preimplantation genetic diagnosis (PGD) for future pregnancies.

Conclusion

Identification of causative mutations through exome sequencing aided in the diagnosis of achromatopsia in the siblings and facilitated genetic counseling for future pregnancies. This report further emphasizes the importance of genetic testing in similar cases. It highlights that exome sequencing is a superior diagnostic approach when combined with routine testing, particularly for achromatopsia and other diseases where relying solely on clinical examinations can lead to misdiagnosis. This case report also presents the first reported case of achromatopsia in India, underscoring the significance of genetic testing in such cases.

Abbreviations

PGD Preimplantation genetic diagnosis
ERG Electroretinogram

Acknowledgements

None.

Author contributions

KP and VM conceived of the presented idea and designed the study. UC and SA and KP performed the examination, evaluated the reports, and verified the analytical methods. VM encouraged KP to investigate and supervised the findings of this work. KP designed the figures and tables. KP, VM, SA, and RA aided in interpreting the results and worked on the manuscript. All authors discussed the results and contributed to the writing of the manuscript.

Funding

NIL.

Availability of data and materials

Not applicable.

Declarations

Ethics approval and consent to participate

Ethical clearance for this study was obtained from the local ethical committee of Institute of Kidney Diseases and Research Centre and Institute of Transplantation Sciences (IKDRC-ITS).

Consent for publication

All consent for publications is taken before submission of manuscript.

Competing interests

The authors declare no competing interests.

Received: 21 April 2023 Accepted: 23 June 2023
Published online: 30 June 2023

References

1. Sharpe LT, Stockman A, Jagle H, Nathans J (1999) Opsin genes, cone photopigments, color vision, and color blindness. In: Gegenfurtner K, Sharpe LT (eds) Color vision: from genes to perception. Cambridge University Press, Cambridge, pp 3–52
2. Thiadens AH, Somervuo V, van den Born LI, Roosing S, van Schooneveld MJ, Kuijpers RW, van Moll-Ramirez N et al (2010) Progressive loss of cones in achromatopsia: an imaging study using spectral-domain optical coherence tomography. Invest Ophthalmol Vis Sci 51:5952–5957
3. Thiadens AA, Slingerland NW, Roosing S, van Schooneveld MJ, van Lith-Verhoeven JJ, van Moll-Ramirez N, van den Born LI, Hoyng CB, Cremers FP, Klaver CC (2009) Genetic etiology and clinical consequences of complete and incomplete achromatopsia. Ophthalmology 116:1984–1989
4. Kohl S, Hamel C (2013) Clinical utility gene card for: achromatopsia—update 2013. Eur J Hum Genet 10:1038
5. Thiadens AA, Roosing S, Collin RW, van Moll-Ramirez N, van Lith-Verhoeven JJ, van Schooneveld MJ, den Hollander AI, van den Born LI, Hoyng CB, Cremers FP, Klaver CC (2010) Comprehensive analysis of the achromatopsia genes CNGA3 and CNGB3 in progressive cone dystrophy. Ophthalmology 117:825–830
6. Aligianis IA, Forshew T, Johnson S, Michaelides M, Johnson CA, Trembath RC, Hunt DM, Moore AT, Maher ER (2002) Mapping of a novel locus for achromatopsia (ACHM4) to 1p and identification of a germline mutation in the alpha subunit of cone transducin (GNAT2). J Med Genet 39:656–660
7. Glöckle N, Kohl S, Mohr J, Scheurenbrand T, Sprecher A, Weisschuh N et al (2014) Panel-based next generation sequencing as a reliable and efficient technique to detect mutations in unselected patients with retinal dystrophies. Eur J Hum Genet 22:99–104
8. Carss KJ, Arno G, Erwood M, Stephens J, Sanchis-Juan A, Hull S, Megy K et al (2017) Comprehensive rare variant analysis via whole-genome sequencing to determine the molecular pathology of inherited retinal disease. Am J Hum Genet 100:75–90
9. Kohl S, Jägle H, Wissinger B et al (2004) Achromatopsia. [Updated 2018 Sep 20]. In: Adam MP, Everman DB, Mirzaa GM et al (eds) GeneReviews®. University of Washington, Seattle, 1993–2022. https://www.ncbi.nlm.nih.gov/books/NBK1418/
10. Park WL, Sunness JS (2004) Red contact lenses for alleviation of photophobia in patients with cone disorders. Am J Ophthalmol 137:774–775

Publisher's Note