Pritti *et al.*
Egyptian Journal of Medical Human Genetics (2024) 25:20
https://doi.org/10.1186/s43042-024-00493-7

Egyptian Journal of Medical Human Genetics

CASE REPORT

Open Access

Novel mutation as a cause of anterior segment dysgenesis leading to blindness in progeny: the genetics decoded!

Kumari Pritti[1*], Vineet Mishra[2], Somesh Aggarwal[4], Mehul Mistri[5] and Manisha Chhetry[2,3]

Abstract

Background Anterior segment dysgenesis (ASD) disorders comprises of spectrum of developmental conditions affecting the structures of angle of anterior chamber including cornea, iris, and lens. These conditions are characterized by both autosomal dominant and recessive patterns of inheritance often with incomplete penetrance/variable expressivity. A significant overlap among phenotypes attributed to mutations in different ASD genes is well recognized.

Case presentation We present a case involving a 29-year-old pregnant woman referred for genetic screening and counseling. She had a 7-year-old male child with congenital bilateral corneal opacity, and his elder sister also exhibited similar findings. Exome sequencing identified a novel variant in the *CYP1B1* gene in a homozygous state, which was associated with anterior segment dysgenesis. Both parents were found to be carriers of the same variant, while the sister had the same variant in a homozygous state. Genotype–phenotype correlation was performed, and it was concluded that the novel variant could be responsible for the eye changes in both siblings. The parents sought prenatal diagnosis for the current pregnancy, which was deemed possible.

Conclusions This case underscores the importance of genetic testing in such rare diseases, as it can assist in early diagnosis, management, and prognosis. It also aids clinicians and parents in making decisions regarding the continuation of the pregnancy at the appropriate time.

Keywords Anterior segment dysgenesis, Novel mutation, Peters anomaly, Variants of uncertain significance

Background

Anterior segment dysgenesis (ASD) is the failure of normal development of tissues in the anterior segment of the eye, affecting anterior chamber structures and associated with an increased risk of glaucoma and corneal opacity [1]. ASD includes a spectrum of developmental conditions affecting the cornea, iris, and lens. The cause is multifactorial, with many genes involved in eye development [2].

ASD is a subject of paramount importance within the field of ophthalmology due to its potential to cause visual impairment and its association with an increased risk of ocular comorbidities, including glaucoma and corneal opacity. Understanding the genetic underpinnings and molecular mechanisms behind these disorders is crucial

*Correspondence:
Kumari Pritti
preeti.ikdrc@gmail.com
[1] Genetics Division, Department of Obstetrics and Gynecology, Institute of Kidney Diseases and Research Center, Dr. HL Trivedi Institute of Transplantation Sciences (IKDRC-ITS), Civil Hospital Campus, Asarwa, Ahmedabad 380016, India
[2] Present Address: Department of Obstetrics and Gynecology, Institute of Kidney Diseases and Research Center, Ahmedabad, India
[3] Department of Obstetrics and Gynecology, B.P. Koirala Institute of Health Sciences, Dharan, Nepal
[4] M & J Regional Institute of Ophthalmology, Ahmedabad, India
[5] Neuberg Center for Genomic Medicine, Ahmedabad, India

for accurate diagnosis, appropriate management, and the development of potential therapeutic interventions.

These anomalies may manifest in isolation or in various combinations, leading to distinct subtypes of ASD with diverse clinical characteristics. Additionally, ASD disorders can sometimes extend their impact beyond the eye, affecting other organ systems, further emphasizing the complexity of these conditions.

Case presentation

A 29-year-old woman, in her third pregnancy at 14 weeks of gestation, was referred to our center for genetic screening. She had a non-consanguineous marriage and had previously delivered two term pregnancies, with both children presenting congenital bilateral cataracts resulting in near-complete blindness. Both parents appeared phenotypically normal, and no other family members were affected. The first child was an 11-year-old girl, and the second child was a 7-year-old boy. Antenatal and natal histories were uneventful, with no history of infections during pregnancy. Both children were delivered normally at full term. Ocular examination of the affected male child (Fig. 1) revealed that he could perceive light and hand movements in the right eye, but the projection of rays was defective. He could count fingers up to 2 m with his left eye. The intraocular pressure (IOP) in the left eye was 22 mmHg. Slit lamp examination of the left eye showed central leucomatous corneal opacity, ectropion uveae, a deep anterior chamber, and buphthalmos (Fig. 2). In the right eye, there was total corneal opacity with a failed corneal graft, rendering it non-functional (Fig. 3). Ultrasound findings of the left eye revealed a few moderate-intensity dot-like echoes, while the right eye showed high-intensity dot-like echoes filling the entire vitreous cavity, retino-choroidal thickening, and the absence of the T sign (Figs. 4, 5). Fundus evaluation was inconclusive due to media opacity. The patient was healthy systemically, with normal stature and build, no facial dysmorphism, no hearing abnormalities, normal mental health, and no cardiac, neurological, skeletal, or genitourinary abnormalities. A diagnosis of unilateral Peters anomaly Type I was made, with trabeculodysgenesis in the fellow right eye.

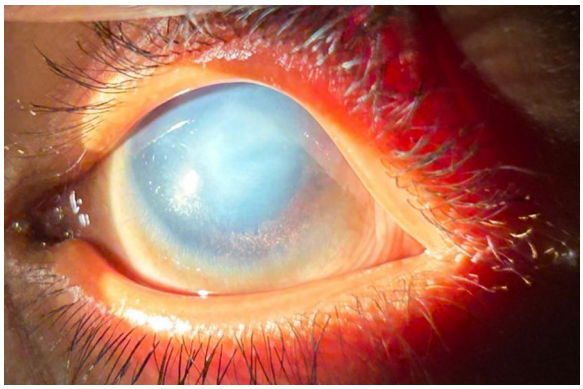

Fig. 2 Slit lamp view of Left eye showing Central leucomatous corneal opacity, ectropion uvae, deep Anterior chamber and buphthalmos

The clinical exome sequencing report of the elder sibling, using next-generation sequencing (NGS), revealed a homozygous variant c.92*C*>*A* (p.Ala31Asp) in exon 2 of the *CYP1B1* gene, classified as a variant of uncertain significance (VUS). Sanger analysis confirmed the same variant in a homozygous state in the other affected male child (Fig. 6). Carrier screening showed that the parents both carried the same variant in a heterozygous state, indicating autosomal recessive inheritance. Genetic screening was sought to assess the risk to the current fetus. Amniocentesis of the pregnant woman, followed

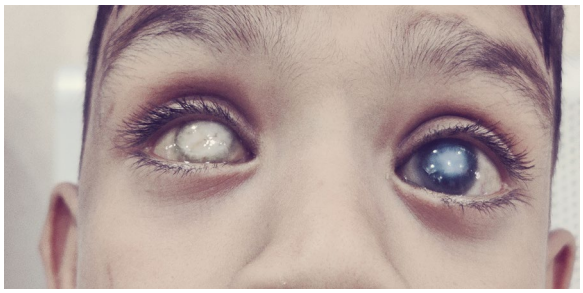

Fig. 1 Affected male child with right eye phthisis bulbi and left eye congenital cataract

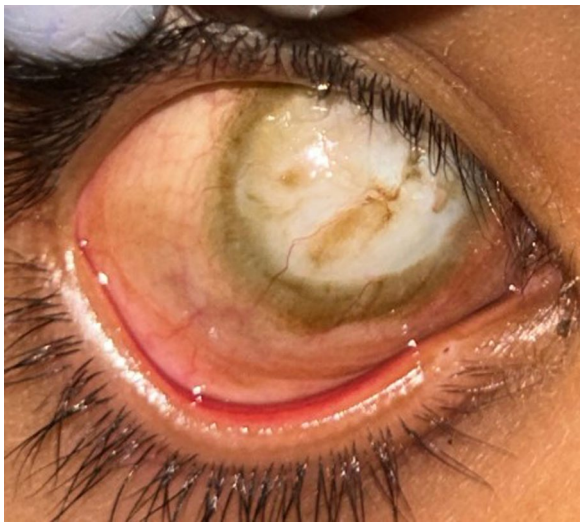

Fig. 3 Slit lamp view of Right eye showing total corneal opacity, failed corneal graft; Pthysical eye

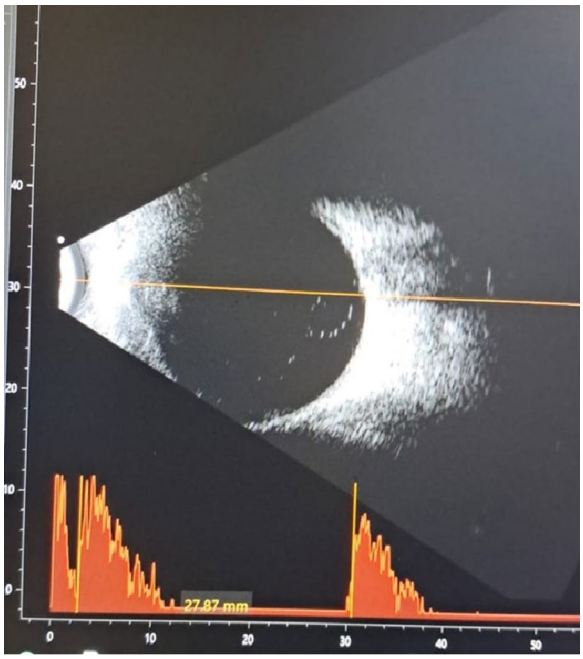

Fig. 4 USG of left eye showing few dot like echoes of moderate intensities

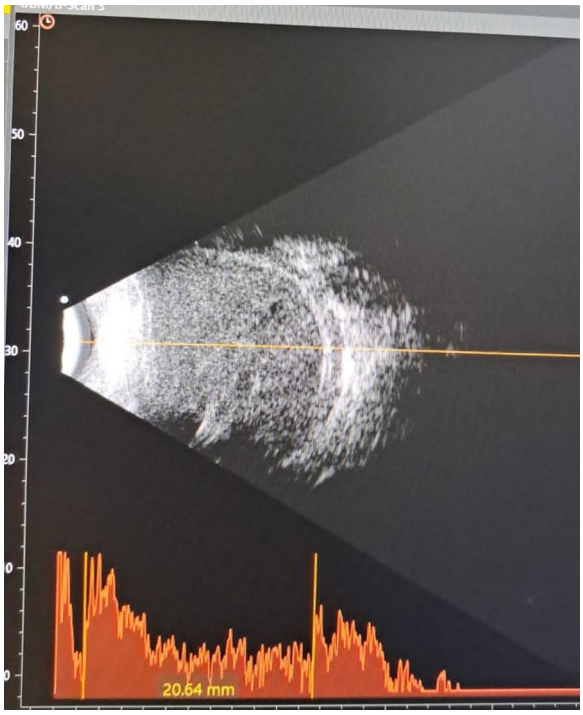

Fig. 5 USG image of Right eye showing high intensity dot like echoes filling entire vitreous cavity, retini-choroidal thickening, No T sign

by Fluorescence in situ hybridization (FISH) and Sanger variant analysis, indicated that the current pregnancy was unaffected.

Discussion

Anterior segment dysgenesis (ASD) disorders encompass a spectrum of developmental conditions affecting the cornea, iris, and lens, which can have autosomal dominant or recessive inheritance patterns with incomplete penetration or variable expressivity [3]. The ASDs are complex and affect multiple structures which makes it difficult to classify. These can occur alone or in combination, with specific combinations identified such as Axenfeld–Rieger anomaly and Peters anomaly. It is easier to characterize the features of the malformation affecting each anterior segment structure as this avoids the use of different clinical diagnoses to describe the same condition [4]. Several clinical features are found in more than a single condition. Identification of the genes causing ASD has gradually revealed that these conditions are part of a disease spectrum [5].

In the early weeks of human development, morphogenetic movements result into bi-layered embryonic optic cup formation from the forebrain neuroectoderm, and the lens vesicle gets invaginated and separated from the overlying surface ectoderm [6]. By processes of tissue morphogenesis and differentiation, four types of embryonic tissue, the neuroectoderm, the surface ectoderm, the neural crest cells, and mesoderm-derived cells form the mature anterior segment structures giving rise to the cornea, iris, and drainage structures of the iridocorneal angle.

Currently, the identified phenotypic spectrum of ASD includes aniridia, iridogoniodysgenesis, Axenfeld–Rieger anomaly, Peters anomaly, and primary congenital glaucoma [7]. Peters anomaly is characterized by corneal opacity, defects in corneal epithelium and adhesions between iris and cornea or lens and cornea [8, 9]. Ocular anomalies may be associated with systemic symptoms involving single or multiple organs [10, 11]. Ocular defects can lead to increased intraocular pressure (IOP), resulting in glaucoma in around fifty percent of cases [2, 10, 11].

Peters anomaly can be classified into two types [9, 12–18]: Type I is unilateral, with iridocorneal adhesions, corneal opacity, and fewer vitreo-retinal and systemic abnormalities. Type II is usually bilateral, with the lens directly adherent to posterior corneal opacity and more commonly associated with systemic features like craniofacial defects, short stature, etc., also referred to as Peters plus syndrome [18].

Numerous genetic causes for ASD have been identified, with many yet to be accounted for. The most common

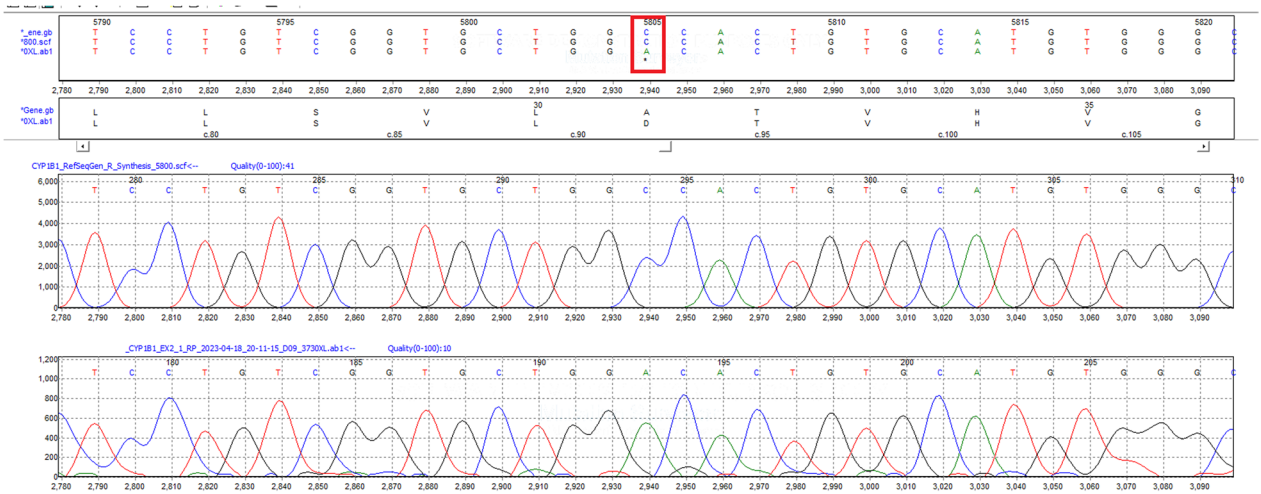

Fig. 6 Sanger sequencing chromatogram of younger male sibling showing homozygous status for c.92*C*>*A* (p.Ala31Asp) in exon 2 of the *CYP1B1* gene

inheritance pattern is autosomal dominant. Most characterized ASD genes encode transcription factors, with several representing extracellular matrix-related proteins. These genes are believed to act together to specify a population of mesenchymal progenitor cells, mainly of neural crest origin, as they migrate anteriorly around the embryonic optic cup. These genes are responsible for mesenchymal cell differentiation which eventually give rise to distinct anterior segment tissues. Development appears critically sensitive to gene dosage. Commonly identified genes associated with ASD and autosomal dominant inheritance include *PAX6, JAG1, PITX2, PITX3, FOXC1, FOXE3, BMP4,* and *COL4A1*. Those associated with autosomal recessive inheritance include *CYP1B1, LAMB2,* and *B3GALTL* [2, 19]. There is evidence that even more genes are involved. The range of ASD phenotypes is diverse, and mutations in the same gene may result in different phenotypes, with many novel mutations yet to be discovered.

PAX6 and *FOXC1* are the most common gene mutations associated with Peters anomaly, while mutations in the *CYP1B1* gene have also been reported [20, 21]. However, the missense c.92*C*>*A* (p.Ala31Asp) variant in the *CYP1B1* gene has not been reported previously as a pathogenic variant or benign variant, to our knowledge. The p.Ala31Asp variant is novel in gnomAD Exomes and 1000 Genomes. The amino acid alanine at position 31 is changed to aspartate, altering the protein sequence and potentially its composition and physiochemical properties. Segregation analysis on the Sanger platform in both parents revealed the same mutation in a heterozygous state, and both affected children showed the same mutation in a homozygous state, confirming that this variant is pathogenic and responsible for the clinical manifestations in both children.

Primary congenital glaucoma has been found to be associated with homozygous or compound heterozygous mutations in CYP1B1 [22]. Few studies have identified mutations in individuals with isolated Peters or Axenfeld–Rieger anomaly, typically in association with glaucoma [23–26]. In a study, eight cases were identified with homozygous/compound heterozygous mutations having mild ectropion uveae, partial aniridia, and congenital glaucoma, further expanding the ocular phenotype associated with CYP1B1 mutations [27].

The use of novel technologies, such as whole-genome sequencing and exome sequencing is likely to expand the spectrum of mutations in known genes and assist in the identification of novel causative genes as well as modifiers that explain the phenotypic variability of ASD conditions [4, 19, 20]. These technologies are widely used in the diagnosis and deeper understanding of the genetics of anterior segment disorders [28]. The widespread availability and use of these genetic technologies also help clinicians and parents make informed decisions regarding the continuation of pregnancies, prognostication, and enrollment in targeted gene therapy trials.

Conclusions

Anterior segment dysgenesis disorders have heterogeneous presentations with incomplete penetration or variable expressivity. Clinical classification of such complex disorder with overlapping clinical features becomes extremely difficult. However, identification of the genes responsible for ASD has gradually led to the recognition that these conditions are part of a disease spectrum.

Novel technologies such as whole-genome sequencing, exome sequencing, and comparative genomic hybridization are potentially effective tools for expanding our understanding of anterior segment dysgenesis disorders. Prenatal screening using these methods can assist clinicians and parents in making informed decisions regarding pregnancy.

Abbreviations

ASD	Anterior segment dysgenesis
IOP	Intraocular pressure
VUS	Variant of uncertain significance
gnomAD	Genome aggregation database
FISH	Fluorescent in-situ hybridization
NGS	Next generation sequencing

Acknowledgements
We wish to thank the family members for their participation in this study.

Author contributions
KP and VM conceived of the presented idea and designed the study. MM and MC and SA performed the examination, evaluated the reports, and verified the analytical methods. VM encouraged KP to investigate and supervised the findings of this work. KP and MM designed the figures. KP, VM, SA, and MC aided in interpreting the results and worked on the manuscript. All authors discussed the results and contributed to the writing of the manuscript.

Funding
Nil.

Availability of data and materials
The data that support the findings of this study are available from the corresponding author upon reasonable request.

Declarations

Ethics approval and consent to participate
Ethical clearance for this study was obtained from the local ethical committee of Institute of Kidney Diseases and Research Center.

Consent for publication
Written informed consent was obtained from the parents of the patient for this publication.

Competing interests
The authors declare no competing interests.

Received: 18 September 2023 Accepted: 28 January 2024
Published online: 10 February 2024

References

1. Waring GO, Rodrigues MM, Laibson PR (1975) Anterior chamber cleavage syndrome. A stepladder classification. Surv Ophthalmol 20:3–27
2. Kaushik S, Dubey S, Choudhary S, Ratna R, Pandav SS, Khan AO (2022) Anterior segment dysgenesis: insights into the genetics and pathogenesis. Indian J Ophthalmol 70(7):2293–2303
3. Cheong SS, Hentschel L, Davidson AE et al (2016) Mutations in CPAMD8 cause a unique form of autosomal-recessive anterior segment dysgenesis. Am J Hum Genet 99(6):1338–1352. https://doi.org/10.1016/j.ajhg.2016.09.022
4. Idrees F, Vaideanu D, Fraser SG, Sowden JC, Khaw PT (2006) A review of anterior segment dysgeneses. Surv Ophthalmol 51:213–231
5. Alward WL (2000) Axenfeld–Rieger syndrome in the age of molecular genetics. Am J Ophthalmol 130:107–115
6. Sowden J (2007) Molecular and developmental mechanisms of anterior segment dysgenesis. Eye 21:1310–1318
7. Kuang L, Zhang M, Wang T et al (2023) The molecular genetics of anterior segment dysgenesis. Exp Eye Res 234:109603
8. Spencer WH (1996) Ophthalmic pathology: an atlas and textbook, vol 1, 4th edn. W.B. Saunders Company, Philadelphia
9. Bhandari R, Ferri S, Whittaker B, Liu M, Lazzaro DR (2011) Peters anomaly: review of the literature. Cornea 30:939–944
10. Lubin JR (1981) Oculocutaneous albinism associated with corneal mesodermal dysgenesis. Am J Ophthalmol 91:347–350
11. Jorgenson RJ, Levin LS, Cross HE, Yoder F, Kelly TE (1978) The Rieger syndrome. Am J Med Genet 2:307–318
12. Yang LL, Lambert SR (2001) Peters' anomaly. A synopsis of surgical management and visual outcome. Ophthalmol Clin N Am 14(3):467–477
13. Almarzouki HS, Tayyib AA, Khayat HA, Alsulami RE, Alzahrani SM, Alkahtani AS, Alghifees LS (2016) Peters anomaly in twins: a case report of a rare incident with novel comorbidities. Case Rep Ophthalmol 7(3):186–192
14. Kenyon KR (1975) Mesenchymal dysgenesis in Peter's anomaly, sclerocornea and congenital endothelial dystrophy. Exp Eye Res 21(2):125–142
15. Sault RW, Sheridan J (2013) Peters' anomaly. Ophthalmol Eye Dis 5:1–3
16. Zaidman GW, Flanagan JK, Furey CC (2007) Long-term visual prognosis in children after corneal transplant surgery for Peters anomaly type I. Am J Ophthalmol 144(1):104–108
17. Van Schooneveld MJ, Delleman JW, Beemer FA, Bleeker-Wagemakers EM (1984) Peters'-plus: a new syndrome. Ophthalmic Paediatr Genet 4(3):141–145
18. Thompson EM, Winter RM, Baraitser M (1993) Kivlin syndrome and Peters'-Plus syndrome: are they the same disorder? Clin Dysmorphol 2(4):301–316
19. Sowden JC (2007) Molecular and developmental mechanisms of anterior segment dysgenesis. Eye (Lond) 21:1310–1318
20. Reis LM, Semina EV (2011) Genetics of anterior segment dysgenesis disorders. Curr Opin Ophthalmol 22(5):314–324. https://doi.org/10.1097/ICU.0b013e328349412b
21. Weh E, Reis LM, Happ HC, Levin AV, Wheeler PG, David KL, Carney E, Angle B, Hauser N, Semina EV (2014) Whole exome sequence analysis of Peters anomaly. Hum Genet 133(12):1497–1511
22. Stoilov I, Akarsu AN, Sarfarazi M (1997) Identification of three different truncating mutations in cytochrome P4501B1 (CYP1B1) as the principal cause of primary congenital glaucoma (Buphthalmos) in families linked to the GLC3A locus on chromosome 2p21. Hum Mol Genet 6:641–647
23. Vincent A, Billingsley G, Priston M et al (2001) Phenotypic heterogeneity of CYP1B1: mutations in a patient with Peters' anomaly. J Med Genet 38:324–326
24. Edward D, Al Rajhi A, Lewis RA et al (2004) Molecular basis of Peters anomaly in Saudi Arabia. Ophthalmic Genet 25:257–270
25. Vincent A, Billingsley G, Priston M et al (2006) Further support of the role of CYP1B1 in patients with Peters anomaly. Mol Vis 12:506–510
26. Chavarria-Soley G, Michels-Rautenstrauss K, Caliebe A et al (2006) Novel CYP1B1 and known PAX6 mutations in anterior segment dysgenesis (ASD). J Glaucoma 15:499–504
27. Khan AO, Aldahmesh MA, Al-Abdi L et al (2011) Molecular characterization of newborn glaucoma including a distinct aniridic phenotype. Ophthalmic Genet
28. Donato L, Alibrandi S, Scimone C et al (2022) The impact of modifier genes on cone-rod dystrophy heterogeneity: an explorative familial pilot study and a hypothesis on neurotransmission impairment. PLoS ONE 17(12):e0278857

Publisher's Note